

See discussions, stats, and author profiles for this publication at: <https://www.researchgate.net/publication/235378892>

Petechial hemorrhages of the tympanic membrane in attempted suicide by hanging: A case report

Article in *Journal of Forensic and Legal Medicine* · February 2013

DOI: 10.1016/j.jflm.2012.05.007 · Source: PubMed

CITATIONS

10

READS

1,559

6 authors, including:



[Eva Rye Rasmussen](#)

Rigshospitalet

64 PUBLICATIONS 628 CITATIONS

[SEE PROFILE](#)



[Michael Larsen](#)

University of Copenhagen

22 PUBLICATIONS 391 CITATIONS

[SEE PROFILE](#)



[Klaus Qvortrup](#)

University of Copenhagen

152 PUBLICATIONS 6,052 CITATIONS

[SEE PROFILE](#)

Contents lists available at [SciVerse ScienceDirect](http://www.sciencedirect.com)

Journal of Forensic and Legal Medicine

journal homepage: www.elsevier.com/locate/jflm

Case report

Petechial hemorrhages of the tympanic membrane in attempted suicide by hanging: A case report[☆]

Eva Rye Rasmussen MD Specialist registrar (ST)/resident of ENT^{a,*,d}, Per Leganger Larsen MD Consultant^a, Kjeld Andersen MD Pre-registration house officer^b, Michael Larsen MD Clinical assistant^c, Klaus Qvortrup MD, PhD Professor^c, Hans Petter Hougen MD, PhD Dr. Med., Professor^b

^aHilleroed Hospital, Dyrehavevej 29, Ear-, Nose- and Throat Department, 3400 Hilleroed, Denmark

^bRigshospitalet, Copenhagen, Dep. of Forensic Medicine, Denmark

^cUniversity of Copenhagen, Dep. Biomedical Science, Denmark

ARTICLE INFO

Article history:

Received 10 March 2012

Received in revised form

23 April 2012

Accepted 29 May 2012

Available online xxx

Keywords:

Strangulation

Hanging

Ear bleeding

Petechial hemorrhages

Tympanic membrane

ABSTRACT

It is important to determine whether a person has been strangulated and the diagnosis is not always straightforward since ligature marks are not always present. In forensic medicine the physical examination recommended is careful inspection of the head and neck region, oral cavity, examination of the eyes including the conjunctiva on both the upper and lower eyelids and photo documentation. Petechial hemorrhages of the conjunctiva are considered marker of life threatening hanging or strangulation. Hemorrhage from ears, perforated tympanic membrane and haematotympanum are scarcely described in case reports of strangulated patients. To our knowledge we are the first to report petechial hemorrhages of the tympanic membrane in a patient following attempted suicide by hanging. We believe that the petechial hemorrhages develop from the capillaries located in lamina propria of the epidermal layer above the fibrous layer. This assumption is made on the basis of our assessment of a normal tympanic membrane with light microscopy. Petechial hemorrhages of the tympanic membrane might in fact be the only sign of life threatening pressure applied to the neck. This is a very important finding and prospective studies should be conducted for further clarification on the matter.

© 2012 Elsevier Ltd and Faculty of Forensic and Legal Medicine. All rights reserved.

1. Introduction

Hanging is the appliance of gravitational pressure on the circumference of the neck by suspension of the body by a form of ligature, e.g. a rope, wire or clothes. In the vast majority of cases hanging is suicidal or accidental, however homicidal hanging have been described, though it is an extremely rare phenomenon.¹ In complete hanging the rapid and forceful appliance of gravitational pressure on the neck constricts both the arteries and the veins, typically with no resulting visible petechial hemorrhages (PH). However, in incomplete hanging the gravitational pressure on the neck is exerted to a lesser extent resulting in no arterial and only

partial venous compression and hence facial congestion, cyanosis and PH.²

Both complete and incomplete hangings are potential life-threatening incidents that involve at least one mechanism that interferes with the oxygenation of the brain. Compression of the large vessels of the neck causes cerebral ischemia and/or compression of the larynx or trachea causes asphyxia.

It is important to determine whether a person has been strangulated and the diagnosis is not always straightforward since ligature marks are not always present. In forensic medicine the physical examination recommended is careful inspection of the head and neck region, oral cavity, examination of the eyes including the conjunctiva on both the upper and lower eyelids and photo documentation³. PH of the conjunctiva are considered marker of life threatening hanging.³ Hemorrhage from ears, perforated tympanic membrane and hematotympanum are scarcely described in case reports of strangulated patients.⁴ To our knowledge we are the first to report PH of the tympanic membrane in a patient following pressure applied to the neck.

[☆] This article is attributable to work done at Hilleroed Hospital, Dyrehavevej 29, Ear-, Nose- and Throat Department, 3400 Hilleroed, Denmark.

* Corresponding author. Tel.: +45 51901503.

E-mail address: eva.rye.rasmussen@dadlnet.dk (E.R. Rasmussen).

^d Present address: Koege Hospital, Ear-Nose-Throat Department, Lykkebækvej 1, 4600 Koege, Denmark.

2. Case report

A middle-aged otherwise healthy male was admitted to the emergency department after a suicide attempt by hanging. The patient had placed a rope around his neck and jumped from a short pile of books. After some minutes he realized that he would not pass out or die due to the insufficient distance of the jump. He was able to release himself and drive to the emergency department where the oto-rhino-laryngologist admitted him. At the physical examination he was fully conscious with a Glasgow Coma Scale score of 15. The only outer sign of hanging was ligature hanging marks around the neck. Laryngeal osteo-cartilaginous injury or conjunctival PH was not observed. At the otomicroscopic assessment PH of the tympanic membranes were surprisingly discovered bilaterally (Fig. 1). The patient was observed for 24 h for potential tardive laryngeal edema and was subsequently discharged with no physical sequelae.

3. Discussion

The tympanic membrane consists of tissue from all three germ layers, the external surface consisting of skin (ectoderm), the middle layer of fibrous tissue (mesoderm) and the internal surface of mucosa (endoderm) (Fig. 2). Blood supply to the external layer of the tympanic membrane derives from the deep auricular branch of the maxillary artery and ramifies beneath the cutaneous stratum. The internal mucosal surface is supplied by the stylomastoid branch of the posterior auricular artery and the tympanic branch of the maxillary artery, which are distributed on the mucosal surface (Fig. 2). Veins drain through the external jugular vein, the transverse sinus, veins of dura mater and the venous plexus on the eustachian tube.⁵

Whether the PH develop in the external or internal layer of the tympanic membrane is unknown, but there are two mechanisms through which they could ensue. The first and most probable is attributable to the mechanical compression of the veins of the neck causing congestion of the veins in both the external and internal layer of the tympanic membrane. The second is based on the knowledge that forced respiratory effort against closed glottis can cause facial PH and rupture of the tympanic membrane.⁶ There have however not been reports on tympanic PH during child birth and similar situations, which gives this mechanism less credibility as the cause of our findings. Compression of the larynx or trachea

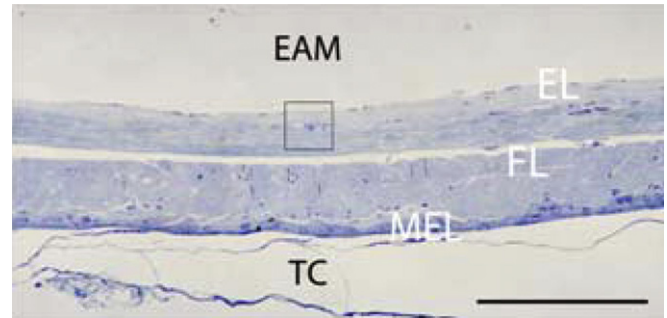


Fig. 2. Light micrograph, cross section of pars tensa in a post mortem human tympanic membrane, which separates the external acoustic meatus (EAM) and the tympanic cavity (TC). The tympanic membrane has three layers (strata): The epidermal layer (EL), which is continuous with the thin skin of the external acoustic meatus, the fibrous layer (FL), and an inner mucosal epithelial layer (MEL), which continues as the mucosa that lines the tympanic cavity. A capillary (box) is located between the epidermal and the fibrous layer. The capillary carries nutrients to the external part of the tympanic membrane. Scale bar: 100 μ m.

simulates closed glottis since the upper respiratory tract is forcefully closed and during hanging or strangulation vigorous respiratory effort is performed.^{6–10} We believe that the PH develop from the capillaries located in lamina propria of the epidermal layer above the fibrous layer. This assumption is made on the basis of our assessment of a normal tympanic membrane with light microscopy (Fig. 2).

PH is observed in various conditions in other parts of the body and occurs in both skin and mucosa.¹¹ Cutaneous PH of the skin in the auditory canal have been described in professional divers,¹² but reports on PH of the tympanic membrane were not encountered when searching MEDLINE database using PubMed and Google Scholar for “petechiae”, “tympanic membrane”, “ear bleeding” and “ear drum”.

A literature search had no positive outcome on a recommendation of routine otoscopic or otomicroscopic assessment in the physical examination of victims of strangulation. PH of the tympanic membrane might in fact be the only sign of life threatening pressure on the neck. This is a very important finding and prospective studies should be conducted for further clarification on the matter.

Conflict of interest

The authors declare that they have no conflicts of interests.

Funding

No funding was raised to produce this manuscript.

Ethical approval

This manuscript is in accordance with ICMJE's Uniform Requirements for manuscripts submitted to Biomedical journals.

References

- Sharma L, Khanagwal VP, Paliwal PK. Homicidal hanging. *Leg Med (Tokyo)* 2011;**13**:259–61.
- Knight B, Saukko PJ. Fatal pressure on the neck. In: *Knight's forensic pathology*. 3rd ed. London: Arnold; 2004. p. 368–95.
- Plattner T, Bolliger S, Zollinger U. Forensic assessment of survived strangulation. *Forensic Sci Int* 2005;**153**:202–7.
- Shields LBE, Corey TS, Weakley-Jones B, Steward D. Living victims of strangulation: a 10-year review of cases in a metropolitan community. *Am J Forensic Med Pathol* 2010;**31**:320–50.
- Gacek RR. Anatomy of the auditory and vestibular systems. In: Snow JB, Wackym PA, editors. *Ballenger's Otorhinolaryngology, head and neck surgery*. 17th ed. Connecticut: People's Medical Publishing House; 2009. p. 1–14.

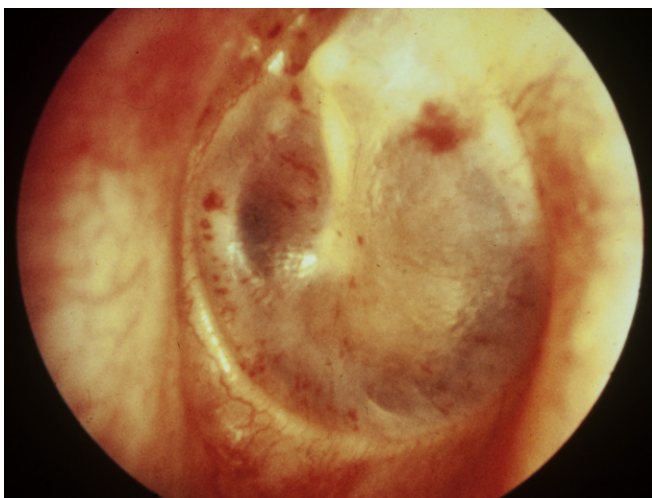


Fig. 1. Petechial hemorrhages in tympanic membrane in attempted suicide by hanging.

6. Baum JD, Rattigan MI, Sills ES, Walsh AP. Clinical presentation and conservative management of tympanic membrane perforation during intrapartum Valsalva maneuver. *Case Rep Med* 2010 [Epub ahead of print].
7. Duband S, Timoshenko AP, Morrison AL, Prades JM, Debout M, Peoc'h M. Ear bleeding: a sign not to be underestimated in cases of strangulation. *Am J Forensic Med Pathol* 2009;**30**:175–6.
8. Amberg R, Strutz J. Differential diagnosis of hematotympanum in forensic autopsy. *Laryngorhinootologie* 1995;**74**:312–6.
9. DiMaio VJ, DiMaio D. *Forensic pathology*. 2nd ed. New York: CRC Press; 2001.
10. Weaver LK, Fairfax WR, Greenway L. Bilateral otorrhagia associated with continuous positive airway pressure. *Chest* 1988;**93**:878–9.
11. Fracasso T, Vennemann M, Klöcker M, Bajanowski T, Brinkmann B, Pfeiffer H, et al. Petechial bleedings in sudden infant death. *Int J Leg Med* 2011;**125**:205–10.
12. Jarrett Anthony. Reversed ear syndrome and the mechanisms of barotraumas. *Br Med J* 1961;**19**:483–6.