

# Guidelines for photography of cutaneous marks and injuries: a multi-professional perspective

**Sam Evans<sup>1,10</sup>, Sonya Baylis<sup>2</sup>, Romina Carabott<sup>3</sup>, Michael Jones<sup>4</sup>,  
Zoe Kelson<sup>5</sup>, Nick Marsh<sup>6</sup>, Jason Payne-James<sup>7</sup>, Jona Ramadani<sup>8</sup>,  
Peter Vanezis<sup>9</sup> and Alison Kemp<sup>10</sup>**

<sup>1</sup>Dental Illustration Unit, School of Dentistry, Cardiff University, Cardiff, U.K. Email: evansst@cardiff.ac.uk

<sup>2</sup>Serious Organised Crime Agency, Bedford, U.K

<sup>3</sup>Expert Forensics LTD, Cardiff, U.K

<sup>4</sup>Institute of Medical Engineering and Medical Physics, Cardiff School of Engineering, Cardiff University, Cardiff, U.K

<sup>5</sup>Smith Institute for Industrial Mathematics and System Engineering, Cardiff, U.K

<sup>6</sup>Metropolitan Police, London, U.K

<sup>7</sup>Forensic Healthcare Services Ltd and Cameron Forensic Medical Sciences Barts & the London School of Medicine & Dentistry, London, UK

<sup>8</sup>Home Office Science - Centre for Applied Science and Technology, U.K

<sup>9</sup>Cameron Forensic Medical Sciences Clinical Pharmacology Barts and the London School of Medicine & Dentistry, London, U.K

<sup>10</sup>Institute of Primary Care & Public Health, School of Medicine, Cardiff University, U.K

**Investigators assessing the likelihood of physical abuse, must make a decision as to whether the injury seen matches the explanation given. In some instances the pattern of these injuries can give the investigator a possible link to the cause of the injury. Thus, matching an injury pattern to an implement or weapon used has forensic implications. The current method of capturing patterned injuries together with poor scale placement often result in some form of distortion that causes a change to the shape of the patterned injury.**

**The aim of this guideline is to assist individuals dealing with the capture of photographic evidence for the investigation of suspected non-accidental patterned cutaneous injuries (PCI), and to ensure high standards of image quality are met for both evidential records and for forensic analysis. The technical equipment specified within these guidelines are recommended by the authors as a basic requirement for imaging best practice, due to their ability to capture detailed and critical data. For precise pattern matching analysis, it is vital that both the injury and the suspected implement are photographed in accordance with this guidance.**

## Introduction

An investigator who is involved in assessing the likelihood of physical abuse, must make a decision as to whether the injury seen matches the explanation given. In some instances the pattern of these injuries can give the investigator a possible link to the cause of the injury<sup>1-8</sup>. This link can be made by careful analysis of the *patterns* that are present in the injury and the extent to which the pattern mirrors the alleged implement used to injure the victim (e.g belt, hairbrush), the slap mark from an alleged perpetrator or reflects an unintentional injury (e.g corner or edge of a piece of furniture). Matching an injury pattern to an implement or weapon used has forensic implications, with regard to the likelihood of physical abuse, thus informing both the investigating team and any legal proceedings. All bruises and cutaneous injuries are photographed as part of the medical and forensic record, child protection and legal record. Photographic imaging is used to record the pattern of the injury, and to facilitate forensic interpretation, not least, it is inappropriate to subject the victim to multiple examinations unnecessarily. Images

can be presented for secondary expert opinion and are presented as legal evidence in court decision making. It is essential that these images are of an optimal quality and free of operator error or induced camera distortion to maximize their usefulness.

The current method of capturing patterned injuries often results in some form of distortion that causes a change to the shape of the patterned injury<sup>4,9,10</sup>. Further error is introduced by the use of inappropriate measuring scales and poor placement of the correct scale next to the injury. Many investigators and photographers are unaware of the errors that are attained by the current 2D photographic method<sup>2</sup>. There are significant challenges in representing a 3D structure (human body) in a 2D space (conventional digital camera). Injuries frequently occur on curved surfaces and are immediately distorted by 2D imaging, chiefly if multiple images are not taken. These errors are easily introduced even by the most experienced and knowledgeable of practitioner. The errors that are introduced can make it impossible for the investigator to measure the features within the injury with any precision. To significantly reduce this photographic distortion in assessment of *bite marks*, and thus improve the supportive evidence that is provided by medical and forensic photographers, it has been proposed that 3D image capture would be more precise, accurate and robust than any other form of recording the bite mark injury. Proponents of 3D imaging technology and many forensic odontologists throughout the world have supported the potential benefits of 3D devices to record bite marks<sup>10,11,12</sup>.

Whilst guidelines have been made available by the British Association of Forensic Odontology (BAFO) and the American Board of Forensic Odontology (ABFO) for the imaging of bite marks<sup>13,14</sup>, and image capture literature has been produced internally by the Association of Chief Police Officers (ACPO) and the National Policing Improvement Agency (NPIA), the Home Office, and the Federal Bureau of Investigation (FBI)<sup>15-17</sup>, there are currently no published peer-reviewed protocols specific to the imaging of patterned injuries. The focus of these guidelines is the recommended use of current 2D digital photographic technologies. The equipment required for conventional photography, as detailed within this paper, is available to all imaging units and professional

photographers within the UK. The authors are of the opinion that a baseline standardised protocol is necessary as an initial step, before considering additional imaging modalities that might further enhance forensic analysis potential, such as cross-polarized<sup>18-23</sup>, infra-red<sup>23,25</sup>, ultraviolet<sup>26-28</sup>, and 3D image capture<sup>29,30</sup>.

Furthermore, these guidelines have been produced with accessibility and adherence in mind. This guide will instruct professionally trained forensic and clinical photographers how to obtain the most accurate and precise evidence possible, with the current gold standard techniques and technologies available. Best practice is to use the services of a professional photographer (<http://www.imi.org.uk/> or the police) to ensure images are of sufficient standard for the courts, however this is not always feasible; hence, this document also aims to assist non-professional photographers by describing basic imaging rules, procedures, and principles to follow.

This paper has been produced by a research group, which is comprised of collaborators from a wide range of disciplines, including law enforcement professionals, forensic investigators, health professionals and photographers. The aims are to assist individuals dealing with the capture of photographic evidence for the investigation of suspected non-accidental patterned cutaneous injuries (PCI), and to ensure high standards of image quality are met for both evidential records and for forensic analysis. The authors recommend following these guidelines for the imaging of patterned cutaneous injuries.

## Protocol Guidelines

The following sections of this paper detail a step-by-by guide for the imaging of patterned injuries.

### 1. Equipment

For best practice in obtaining sufficient images, there are basic equipment requirements.

- Digital Single Lens Reflex (DSLR) camera. Professional or semi - professional grade (e.g Nikon D3, D700, D80) NB. (DSLRs are advisable as smartphones in general produce images that are of poor quality. The use of smartphones or other cameras in

inexperienced hands has the potential for a) failing to convict the guilty, or conversely, b) causing miscarriages of justice.)

- Lens.
  - Prime (macro) e.g Nikon 60mm or 105mm.
- Flashguns.
  - Ideally two balanced, dual mounted flashguns on either side of the camera to ensure even illumination. However reasonable results can be obtained with a suitable single flashgun or ringflash if properly positioned.
- Metric scale.
  - A rigid L shaped scale (ABFO No.2)<sup>30</sup> and longer straight one if required for large patterns. All scales should have a matt finish to reduce reflections. Recent research has indicated that the measurements on scales are not consistent among the various brands<sup>36</sup>.  
A rigid scale (such as the previously mentioned) is essential for the photography of a PCI. Without this scale being placed correctly and photographed with the injury, further analysis is affected and, results in inadmissible evidence for court. The use of tape or adhesive scales should be avoided.
- An accurate colour chart or grey scale chart.
  - A colour chart should be employed when photographing the bruising. A small mini colour checker will be the most practical to use<sup>31</sup>.

## 2. Preparation

There are a few basic steps to follow prior to photography, required for best practice in gathering photographic evidence.

- The compact flash card should be formatted.
  - There should not be any mixing of forensic cases on the compact flash card. It is very important to maintain the integrity of the sequence of images. Therefore the operator must not delete any of images, even if errors are made in exposure or composition etc.
- Verify camera date & time
  - This will ensure that the correct date and time is embedded within the metadata of the digital images
- Image file formats
  - This determines the safe level of adjustments that can be made to the image and it may also be important in

demonstrating the integrity of the image as evidence.

The recommended file format for capturing images of injuries is the RAW file, where the image captured by the image sensor is stored with minimal processing. This 'as captured' data is essentially a digital equivalent of the 'negative' in conventional photography.

Each camera will have its own RAW file format and therefore Adobe Photoshop® or specialist software (supplied with the camera) is required to open and process these images. RAW files contain greater bit depth colour information than alternative file formats, and can therefore undergo far greater adjustments (e.g. contrast, brightness, levels) without significant image degradation.

As RAW files hold the greatest possible information for the user, they are the preferred file format for demonstrating the integrity of the image.

If RAW files are not supported by the camera being used and/or the organisation taking the images, a TIFF (tagged image file format) file format should be used instead. This is a widely supported file format that includes metadata describing the attributes of the image, and has minimal processing or compression applied to it.

The final file format available for capturing images is the JPEG (joint photographic experts group) file, which is most commonly used. It is not a format recommended for primary capture of images that will be used for forensic casework because of the compression loss that is associated with these images<sup>16,17,32</sup>. JPEGs may be created from a RAW file for subsequent ease of transmission and display, but the RAW file should always be retained as the primary evidence. If JPEG images are to be used they must be captured at the highest possible image quality with no additional compression applied.

Compression is applied to the image a multitude of times when it is first captured, when it is processed and every time it is re-saved, so there are potential issues with image degradation. These may not be immediately evident, but may remove important detail or lead to the image integrity being questioned and therefore the sole use of JPEG format for imaging of injuries is not recommended.

## 3. Correct positioning of camera to injury

Forensic analysis of PCI is severely affected by distortion. This distortion can be categorised

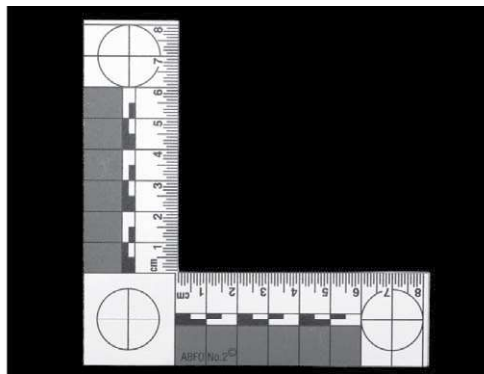
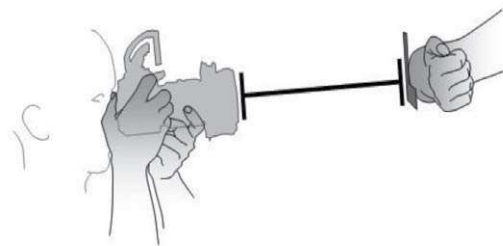


Figure 1. The correct positioning-No distortion produced.

into two types of distortion, primary and secondary, as described by Sheasby and MacDonald<sup>9</sup>. Primary distortion is due to the process in action at the time of impact, which includes two categories, dynamic (the interaction of the implement and skin) and tissue (stretching and swelling of the skin etc.). Secondary distortion is broken down into three categories: time-related changes, body position, and photographic distortion. Photographic distortion is one of the few controllable variables in the whole process of the forensic analysis.

Any distortion in the image may hamper attempts to produce viable evidence for court. Research has shown that if a wound or a feature on the body is photographed at more than a 15 degree angle<sup>29</sup> to the perpendicular, then distortion would be visible within the image. An angle of less than 15 degrees will still.

There are three main types of photographic distortion that are prevalent in photographing PCI, detailed<sup>33</sup>. To try and

avoid such error the following steps in correct 'camera to scale to injury' placement should be adhered to.

- Type 1.
  - When taking the photographs, the film plane (CCD or CMOS sensor) of the camera must be perpendicular to the plane of the injury (Fig 1.). If the photographer fails to do this then Type 1 (Fig 2.) distortion will take place. This is called angular distortion.
- Type 2.
  - The scale must be placed on the surface of the skin. This will ensure the scale is on the same plane as the injury (Fig 3.). If the scale is not on the same plane as the injury then there will be Type 2 distortion. (Fig 4.)
- Types 3 and 4.
  - Applying too much pressure when it is placed next to the injury can warp a portion of the scale. (Fig 5.) Furthermore if the scale is tilted it will cause error.

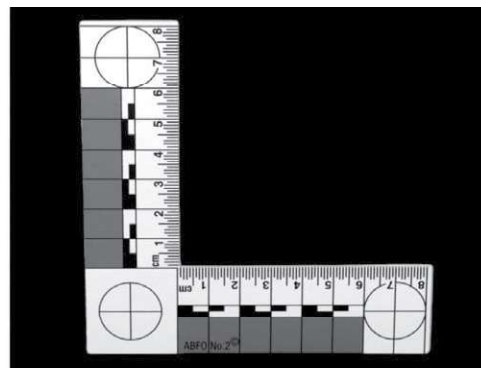
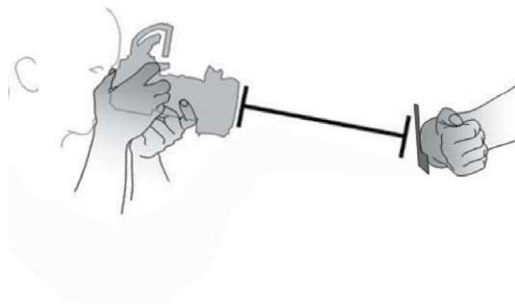


Figure 2. Incorrect positioning-Type 1 distortion (angular).

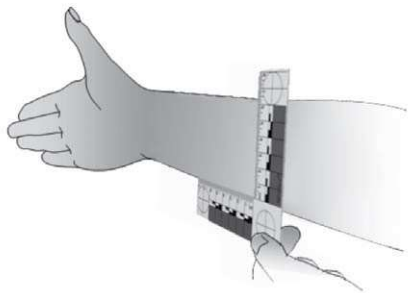


Figure 3. Correct position-No distortion produced.

Incorrect orientation (a) and bending (b) of the scale.

The scale should be close to the injury, but not so close as to obscure any outlying less obvious marks.

It is important to include all of the circles to identify any angular distortion. It has been mentioned in some research studies that such distortion can be digitally corrected. However, any digital "correction" of an image with angular distortion may result in the interpolation of the pixels. If interpolation takes place, then the digital evidence falls under the banner of "Reconstruction". According to National Policing Improvement Agency (NPIA) guidance<sup>15</sup> reconstruction can only be applied as a graphical interpretation and cannot be presented as a true image. However, when geometric restoration is applied, if used correctly, it can be said to be admissible as evidence. As mentioned by Sheets and Bush<sup>34</sup>. Many standard image processing software packages do not

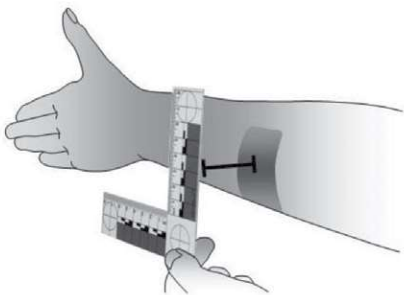


Figure 4. Incorrect position - Type 2 distortion.

offer the ability to control the image with mathematical algorithms for a safe geometric restoration.

#### 4. Sequence of images of injury

This list of images to capture, and in what order, should be followed for best practice:

1. Image of person's I.D (patient label, consent form, etc.)
2. Image of person's face
3. Location shot showing injury and identifying anatomical area, without a scale (for example, the whole arm or full face or leg)
4. Close up shots of the injury, including the whole of the scale (all 3 circles of ABFO No. 2 scale must be shown, helping identify any angular distortion)
5. If on a curved surface, then multiple views (at least 3) will be needed
6. If on an area like the chest the position of the body should be taken into account.
7. Detail shots if required
8. Images using photographic filters, different wavelengths (IR, UV), or alternate methods of illumination may be used to record the injury in addition to unfiltered photographs
9. Image of person's I.D

For further information, the next section discusses each aspect of the list in greater detail.

##### 4.1 Image of person's I.D

The image of I.D is needed to link images of injuries to the person being photographed.

##### 4.2 Image of person's face

The image of the face crucially links images of injuries to the subject being photographed.

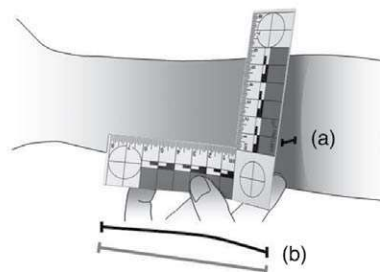


Figure 5. Warping of the scale.

In some situations the subject may object to having their face photographed. The professional staff trying to obtain this image should explain why this image needs to be taken.

*4.3 Location shot showing injury and identifying anatomical area, without a scale*  
This image should illustrate the bruising with the surrounding area, so the viewer will be able to ascertain the anatomical position of the injuries.

*4.4 Close up shots of the image, including the whole of the scale*  
It is crucial that any angular distortion is reduced by following the positioning suggested previously, enabling accurate pattern analysis to be performed on these images.

*4.5 If on curved surface then multiple views will be needed*  
When photographing a PCI on a curved surface, such as the edge of a forearm or bicep<sup>35</sup>, it is vital that the photographer takes images from at least three different angles (Fig 6.). The camera must remain perpendicular to the injury and scale for all images.

For example, if the injury is curved around an arm then the scale must be moved around the curve, ensuring that it is on the same focal plane as the impact site. As demonstrated below:

*4.6 If on an area like the chest the position of the body should be taken into account*  
Any area of the body that is affected significantly by position (e.g. the skin being stretched) should be taken into account<sup>9</sup>. For example, if the injury is on the chest, arms, or torso, then the body should be moved into various positions (Fig 7.) that may be consistent with how the injury might have been obtained.

*4.7 Detail shots if required*  
Detail shots might need to be taken if individual marks can be seen, and are of good evidential value. Areas on small parts of the body such as fingers, ears, and nose might benefit from more detailed views. Any advice should be sought from the forensic specialist supporting the case.

*4.8 Images using photographic filters, specialty film, and alternate methods of illumination may be used to record patterned injury in addition to unfiltered photographs*

*4.9 Image of persons I.D*  
This image is helpful to maintain the integrity of the sequence.

**5. Photography of implement**  
In many situations it is relevant to the investigation to forensically examine the implement that may have caused the PCI. In this case the striking edge of the implement should be photographed employing the same technique used for the injury. This will enable the relevantly trained professional to conduct pattern-matching analysis to a safe standard.

**6. Audit trail of digital images**  
It is important to maintain an audit trail of every change that is made to an image from the moment it is first captured on a camera to the time when it is presented in court. In this way, it can be demonstrated that the image presented in court can be reproduced from the original image using a sequence of repeatable, recognised processes that represents the audit trail. Many professional software packages are equipped with the facility to store changes made in the image via the metadata.

Guidance relating to starting and maintaining an audit trail is provided by the Home Office and ACPO / NPIA guidance<sup>15,16</sup>.

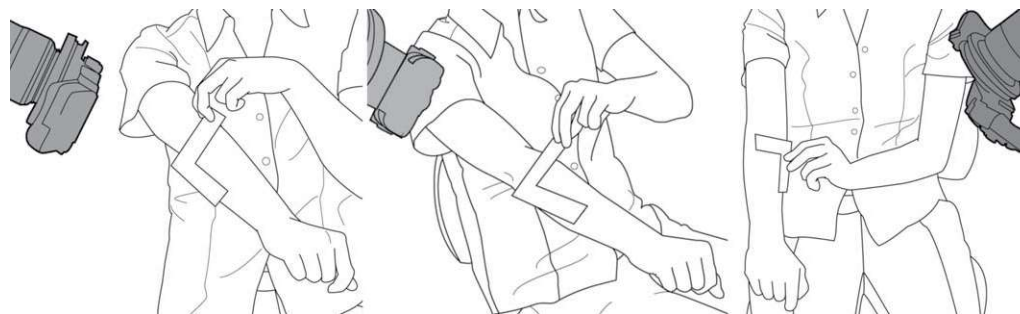


Figure 6. Example of photographing a PCI on a curved surface.

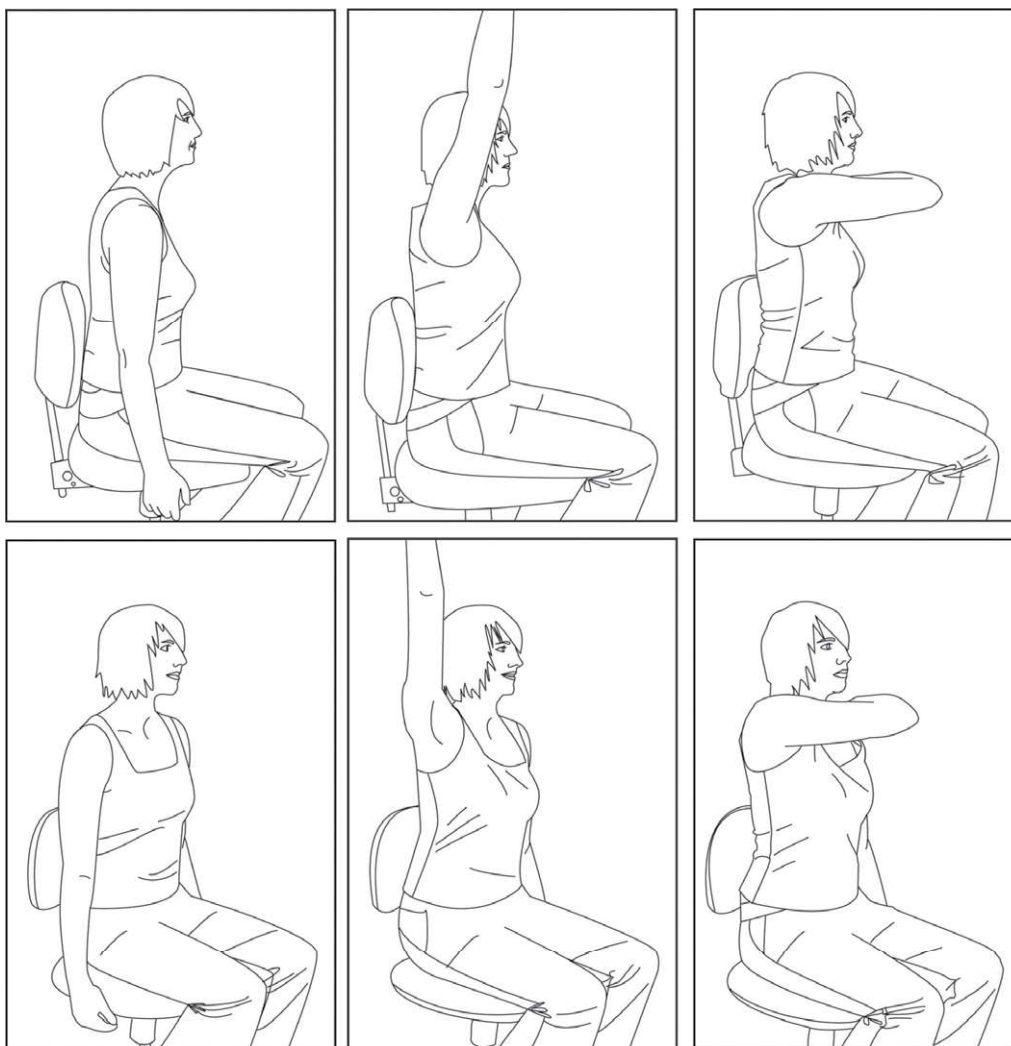


Figure 7. Example positions.

In summary, the recommended procedure is to save a 'Master Copy' of the file from the camera in the original file format (RAW is recommended). This Master Copy may be stored as a Write Once Read Many (WORM) format such as a CD, or on a secure server. This Master Copy must remain unchanged from its original format, but copies may be taken from it for subsequent image processing. These are defined as 'Working Copies'.

Every time an adjustment is made to the Working Copy (e.g. changes in contrast and/or brightness, adjustments to colour saturation) they must be recorded either manually or by the software being used to carry out the adjustments. All adjustments should be in accordance with best practice<sup>15</sup>.

This audit trail must be stored with the

Working Copy, and both the Master Copy and the Working Copy and audit trail must then be archived for the period of time dictated by the requirements of the case. With all of these pieces of evidence in place it will be possible to demonstrate that the Working Copy has been legitimately obtained by progressively adjusting the Master Copy image using recognised procedures, and that the image shown in court is a true representation of what was photographed.

## Discussion and Conclusion

When physical abuse is suspected, it is imperative that the corresponding visible injuries are recorded as precisely as possible.

Photographic Images are invaluable for both evidential records and for forensic comparative analysis of the injury with features or configurations that may be indicative of the implement used, or the physical contact surface of a perpetrator). Furthermore, in order to capture the full extent of any pattern distribution, the injury requires imaging as soon as possible. Thus, a professional photographer should be recruited at the earliest possible convenience. In some instances it may be relevant to re-photograph the PCI at 48, 72 hours or in a few days to record any significant changes.

Most regional based hospitals will have an imaging unit that can be contacted to attain the services of a professional photographer. The local police service will also have photography expertise and can be contacted for imaging. If a professional photographer is unavailable at the time required, it is recommended that photography take place using the next best available resource. This may be an individual with or without experience in photography, who can follow the guidelines detailed within this paper. It is imperative that this protocol is adhered to as much as possible, to ensure the images captured can be used for evidential records and forensic analysis. To adhere to best practice and to obtain the highest quality photographic evidence, it is advised that a professional photographer be requested when they are next available.

The technical equipment specified within these guidelines are recommended by the authors as a basic requirement for imaging best practice, due to their ability to capture detailed and critical data. However, whilst the standard of equipment is important, it is appreciated that under some circumstances the recommended equipment may not be available to the individual capturing the images at the time required. Since injuries are time sensitive, with visible patterns of injury diffusing over time, (especially bruises) the authors suggest capturing images with sub-optimal equipment when necessary to do so. However caution should be used, especially the use of mobile phones as cameras. In spite of the fact that these devices have sensors with large pixel counts the lenses used are likely to have short focal lengths. (The focal length on many mobile phones is equivalent to around 30mm in a SLR camera, which will cause lens distortion). The lens distortion, the likelihood of pixel noise and lack of tonal range in a

digital image produce by a mobile phone will reduce the quality of the photographic evidence. In order to capture as much detail within the image as possible, and such that the image can be used for evidential records and forensic analysis, the guidelines depicted within this paper must be adhered to.

Once the photographs have been taken, it is important to follow the guidance within this paper for data storage, access, and auditing purposes. All ethical implications need to be considered with regards to consent, anonymity, and data protection in accordance with local and/or national procedures.

This paper considers the current technical equipment available only; whilst further developments in imaging technology are underway, the tools for 3D image capture are not yet readily available to most professional photographers and/or institutions. The authors are aware that these guidelines will require updating as and when these future technologies are introduced. Furthermore, other digital imaging modalities (such as reflective ultraviolet and near infra-red) have undergone some initial investigative research<sup>4,23-28</sup>, and currently require further work to fully demonstrate any possible potential to provide additional information for PCI that are not apparent in the visible spectrum.

When using current 2D cameras (DSLRs) for the image capture of PCI, it is important to consider the limitations of such technology. It is well known how difficult it is to maintain the correct orientation (the camera perpendicular to the injury and scale) in certain conditions, such as when photographing very young children. This practical problem can reduce the level of precision in regard to faithfully reproducing the injury for analysis. Another consideration is the issue of accuracy. It is difficult to identify the true known value of an object, such as a bruise or other dermatological injury. If that true value is unknown, it is not possible to determine how accurate your measurement is. To compound this issue, 2D devices reduce the 3D structure (the human body) into a 2D space, which will cause further deviation from being able to assess the true value of the object.

This collaborative guide has been produced for both professional and non-professional photographers, to ensure sufficient evidence for the analysis of patterned dermatological

injuries is captured during imaging. For precise pattern matching analysis, it is vital that both the injury and the suspected implement are photographed in accordance with this guidance.

## Declaration of interest

The authors report no conflicts of interest. The authors alone are responsible for the content and writing of the paper.

## References

- Evans S. et al. (2014) Focussing on the future: Survey results on the image capture of patterned cutaneous injuries. *Journal of Forensic and Legal Medicine* 24:7–11.
- Child Protection Companion (2006) Guidance for clinicians on how to recognise and manage child abuse and neglect. Royal College of Paediatrics and Child Health, London, 1st Edition. <http://www.rcpch.ac.uk/Policy/Child-Protection/Child-Protection-Publications>.
- Wright FD (1998) Photography in Bite Mark and Patterned Injury Documentation – Part 1. *Journal of Forensic Sciences* 43:4:877–880.
- Marsh. (2010) Injury Photography: Is it more than skin deep? *The Journal of Homicide and Major Incident Investigation*. 6(2).
- Jappie F. Non accidental injuries in children. *Australian Family Physician* 1994;23(6): 1144–1150 [PubMed citation only].
- Murty OP, Ming CJ, Ezani MA, Yan PK, Yong TC. Physical injuries in fatal and non-fatal child abuse cases: A review of 16 years with hands on experience of 2 years in Malaysia. *International Journal of Medical Toxicology and Legal Medicine*. 2006;9(1):33–43.
- Brinkmann B, Püschel K, Mätzsch T. Forensic dermatological aspects of the battered child syndrome. *Aktuelle Dermatologie*. 1979;5(6):217–232.
- Patno K, Jenny C. Who slapped that child? *Child Maltreatment*. 2008;13(3):298–300 [PubMed]
- Sheasby and MacDonald, (2001). A Forensic classification of distortion in human bite marks. *Forensic Science International*. 122(1).
- Evans S, Jones C and Plassmann P. (2012). 3D imaging for bite mark analysis. *Imaging Science Journal*. DOI: 10.1179/1743131X11Y.0000000054.
- Martin-de-Las-Heras et al. (2007) Effectiveness of Comparison Overlays Generated with DentalPrint® Software in Bite Mark Analysis. *Journal of Forensic Science*, 52(1).
- Thali et al. (2003) Bite Mark documentation and analysis: the forensic 3D/CAD supported photogrammetry approach. *Forensic Science International* 135(2).
- BAFO (British Association of Forensic Odontology) Guidelines Bite Mark Methodology (2001) <http://www.bafo.org.uk/resources/bitemarks.php>
- ABFO (American Board of Forensic Odontology) Bite mark Guidelines [http://www.abfo.org/id\\_mark\\_guidelines.htm](http://www.abfo.org/id_mark_guidelines.htm)
- ACPO & NPIA (2007) Practice advice on police use of digital images. Produced on behalf of the Association of Chief Police Officers by the National Policing Improvement Agency. Professional Practice. Available on-line at [Accessed: October 2011]: <http://www.acpo.police.uk/documents/crime/2007/200712CRIADI01.pdf>
- Cohen N, MacLennan-Brown K (2007) Digital Imaging Procedure. Home Office Scientific Development Branch, version 2.1, November 2007, Publication No. 58/07. ISBN: 978-1-84726-559-3.
- FBI Laboratory (2005) Digital Imaging Guidelines. Photographic Operations & Imaging Services Unit, Federal Bureau of Investigation.
- Benson PE, Shah AA, Willmot DR (2008) Polarized Versus Nonpolarized Digital Images for the Measurement of Demineralization Surrounding Orthodontic Brackets. *Angle Orthodontist* 78:2:288–293. doi: 10.2319/121306-511.1.
- Robertson AJ, Tumba KJ (1999) Cross-polarized photography in the study of enamel defects in dental paediatrics. *Journal of Audiovisual Media in Medicine* 22:2:63–70.
- Edwards N, (2011), Cross-polarisation, making it practical. *J Vis Commun Med*; 34(4):165–72.
- Rizova E, Kligman A (2001) New photographic techniques for clinical evaluation of acne. *JEADV* 15:3:13–18.
- Ortonne JP, Gupta G, Ortonne N, Duteil L, Queille C, Malfet P (2009) Effectiveness of cross polarized light and fluorescence diagnosis for detection of sub-clinical and clinical actinic keratosis during imiquimod treatment. *Experimental Dermatology* 1-7. doi: 10.1111/j.1600-0625.2009.01047.x
- Lawson Z, Nuttall D, Young S, Evans S, Maguire S, Dunstan F, Kemp A (2010) Which is the preferred image modality for paediatricians when assessing photographs of bruises in children? *International Journal of Legal Medicine* doi: 10.1007/s00414-010-0532-7.
- Raymond MA, Hall RL (1986) An interesting application of infra-red reflection photography to blood splash pattern interpretation. *Forensic Science International* 31:189–194.
- Tseng S, Grant A, Durkin A (2008) In vivo determination of skin near-infrared optical properties using diffuse optical spectroscopy. *Journal of Biomedical Optics* 13:1:014016.

26. Krauss TC, Warlen SC (1985) The Forensic Science Use of Reflective Ultraviolet Photography. *Journal of Forensic Sciences*, JFSCA 30:1:262–268.
27. David TJ, Sobel MN (1994) Recapturing a Five-Month-Old Bite Mark by Means of Reflective Ultraviolet Photography. *Journal of Forensic Sciences*, JFSCA 39:6:1560–1567.
28. David TJ (1990) Documentation of a Seven Month Old Bite Mark with Ultraviolet Photography. Presented to the Annual Meeting of the American Academy of Forensic Sciences, Cincinnati, February 1990.
29. Evans S et al. (2010) 3D imaging in forensic odontology. *Journal of Visual Communication in Medicine* Vol. 33 (2).
30. Blackwell SA, Taylor RV, Gordon I, Ogleby CL, Tanijiri T, Yoshino M et al. (2005) 3-D Imaging and quantitative comparison of human dentitions and simulated bite marks. *International Journal of Legal Medicine* 121(1):9–17.
31. Hyzer, and Krauss, (1998) The bite mark standard reference scale ABFO No. 2, *Journal of Forensic Science*. 33 (2).
32. Scientific Working Group on Imaging Technologies (SWGIT) Version 1.2 June 2002. *Forensic Science Communications* Vol 5 No. 1 2003.
33. Bowers and R J Johansen, (2000) *Digital analysis of bite mark evidence (Using Adobe® Photoshop®)* 1<sup>st</sup> Ed. USA. Forensic Imaging Services. USA.
34. Sheets HD, Bush MA (2010), Mathematical matching of a dentition to bitemarks: Use and evaluation of affine methods, *Forensic Sci. Int.* doi: 10.1016/j.forsciint.2010.09.013.
35. Freeman et al. (2005). Seven Hundred Seventy Eight Bite Marks: Analysis by Anatomic Location, Victim and Bitter Demographics, Type of Crime, and Legal Disposition. *Journal of Forensic Science*. 50(6).
36. J. Jason Payne-James, (2012) Rules and scales used in measurement in the forensic setting: measured—and found wanting!. *Forensic Science, Medicine, and Pathology*. 8 (4) 482–483.