

THE EXPERT'S CORNER

How to Do and Interpret a Rectal Examination in Gastroenterology

Nicholas J. Talley, M.D., Ph.D., F.A.C.P., F.A.C.G., F.R.A.C.P., F.R.C.P.

Department of Internal Medicine, Division of Gastroenterology & Hepatology, Mayo Clinic College of Medicine, Jacksonville, Florida

(Am J Gastroenterol 2008;103:820–822)

How to do a useful rectal examination may be becoming a lost skill. At a recent major U.S. national meeting, an informal poll of the audience revealed many busy gastroenterologists failed to do a rectal despite the presence of lower gastrointestinal (GI) symptoms. However, the audience seemed thirsty for knowledge on how to perform a decent GI rectal examination, and a number asked for instruction. The technique may be often poorly taught in medical school; in some places, urologists alone instruct students in how to do rectal examinations, which means the prostate may be better assessed but the rest of the examination is largely ignored. Even in GI Fellowship training, adequate instruction and experience may often be lacking based on feedback to the author, albeit anecdotal. A cursory examination at the time of colonoscopy may often be inadequate for identifying key abnormalities, as most of us are focused then on successfully completing the endoscopy safely and as quickly as we can, to keep the list moving. Yet the finger can obtain very useful information quickly, easily, and safely. Indeed, in patients presenting with unexplained chronic constipation or fecal incontinence, the rectal examination can help dictate the most appropriate next set of investigations.

The following simple 10-step approach may help to optimize the performance of an intelligent rectal examination in gastroenterology practice (1):

1. *Reassure the patient:* Explain what you are about to do and why.
2. *Position:* Ask the patient to lie in the left lateral position. Having the patient stand to do the rectal examination, in the bent over position, may help provide good information on the prostate, but will obscure some key information for gastroenterologists.
3. *Inspection:* Look at the perineum by spreading the buttocks after donning a pair of gloves. Abnormalities such as thrombosed external hemorrhoids, skin tags, rectal prolapse, an obvious fissure, anal warts, or evidence of pruritus ani usually from fecal soiling should be easily appreciated. The presence of a scar at the anus correlates with lower incremental anorectal squeeze pressures (2). You won't see anything if you don't look.
4. *Ask the patient to strain:* Watch the perineum. You may see leakage of stool, or the presence of a patulous anus.

A gaping anus often indicates lower resting pressures on anorectal manometry (2). You may see prolapse of internal hemorrhoids. On straining, if there is rectal prolapse, you may observe at the anal verge a dark red mass; radial folds are seen in mucosal prolapse and concentric folds in complete prolapse. The mass is continuous with the perianal skin; it is usually painless. In mucosal rectal prolapse, you can feel the prolapsed mucosa between the thumb and forefinger.

5. *Test the anal wink:* Stroke a cotton pad in all four quadrants around the anus. Usually you will see a brisk anal contraction which indicates the sacral nerve pathways are intact. Sometimes there is a weak response in health. The absence of an anal wink, particularly in the setting of fecal incontinence, should make you suspicious that there is a possible spinal cord problem, and this should direct you to perform a more detailed neurological examination and consider further investigations accordingly.
6. *Start palpation:* Place the tip of your gloved, index finger gently over the anus. I ask the patient to breathe and try to relax; this acts as a distraction. By slowly increasing pressure with the pulp of the finger, the anal sphincter usually relaxes slightly at which time the finger can be painlessly advanced into the rectum. If there is excruciating pain on starting the examination, this strongly suggests that there is an anal fissure in which case the remainder of the rectal examination should be abandoned. Often the fissure can be seen on inspection; an anal fissure can precipitate constipation but may be secondary to constipation itself. By liberally lubricating the rectum with lidocaine jelly, it may still be possible to complete the rest of the examination, but usually I perform anoscopy under appropriate sedation in this setting. Other causes of significant anal pain during palpation include recently thrombosed external hemorrhoids, an ischiorectal abscess, active proctitis, or anal ulceration from another cause.
7. *Assess resting sphincter tone:* As you are moving your finger through the rectum initially, you can gauge resting tone, which is predominantly (70–80%) attributable to the internal anal sphincter muscle (Fig. 1). This should alert you to the presence of reduced sphincter tone, which may indicate a sphincter tear. A high anal resting tone

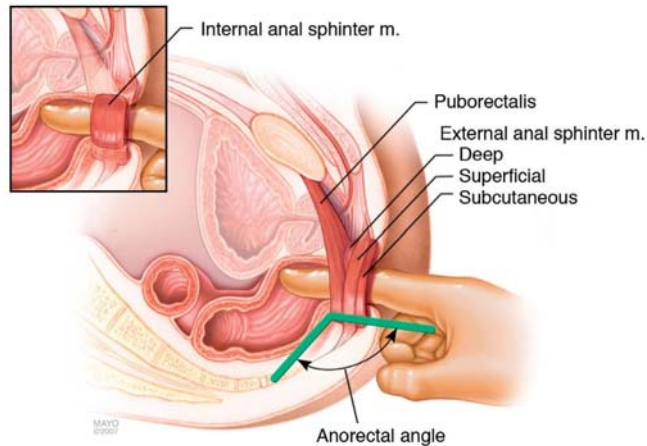


Figure 1. The normal pelvic floor at rest during rectal examination. The internal anal sphincter muscle is normally “hidden” by the external anal sphincter muscles and the puborectalis in the lateral view portrayed; the insert demonstrates the internal anal sphincter.

may be contributing to difficulties with evacuation. There appears to be a good correlation between absent, decreased, and normal resting and squeeze pressures with anorectal manometry (2).

8. *Palpate the rectal walls:* The anterior wall is palpated for the prostate gland in men and the cervix in women. While just examining the prostate is not an adequate screen for prostate cancer, I believe we have an obligation to identify obvious abnormalities and refer these patients if indicated. The presence of a mass above the prostate or cervix may be a sign of a metastasis (on Blumer’s shelf). Rotate the finger clockwise so the lateral walls and posterior walls can be palpated in turn, then advance the finger high into the rectum and slowly withdraw it along the wall; this approach will help identify lesions such as polyps or rectal cancer if they are large enough and in reach. Determine if there may be a rectocele or intussusception. Rotate your examining finger anteriorly. You may feel a defect in the anterior wall of the rectum which suggests a large anterior rectocele.
9. *The pelvic floor—special tests for pelvic floor dysfunction:* The first test is simple: ask the patient to strain and try to push out your finger. Normally, the anal sphincter and puborectalis should relax and the perineum should descend by 1–3.5 cm. If the muscles seem to tighten, particularly when there is no perineal descent, this suggests paradoxical external anal sphincter and puborectalis contraction, which in fact are blocking normal defecation (pelvic floor dyssynergia). Perineal descent assessed by examination correlates with descent assessed by dynamic MRI (3). Second, note if palpation produces pain when pressing on the posterior rectal wall; this suggests puborectalis muscle tenderness, which can also occur in pelvic floor dyssynergia. Third, assess whether the anal sphincter and the puborectalis contract when you ask

your patient to contract or squeeze the pelvic floor muscles. Puborectalis contraction is perceived as a “lift,” that is, the muscle lifts the examining finger toward the umbilicus. Many patients with fecal incontinence cannot augment anal pressure when asked to squeeze. Finally, place your other hand on the anterior abdominal wall while asking the patient to strain again. This provides some information on whether the patient is excessively contracting the abdominal wall (e.g., by doing an inappropriate Valsalva maneuver) and perhaps also the pelvic floor muscles while attempting to defecate, which may impede evacuation. However, the exact value of this test is unclear.

In 100 patients presenting to a tertiary care center for evaluation of constipation, the rectal examination had an impressive sensitivity of 81% for identifying dyssynergia using anorectal manometry as the gold standard (4). Pelvic floor dysfunction causing constipation responds to biofeedback in about 70% of cases, and this treatment can result in a laxative-free existence for patients with troubling outlet constipation (5); the diagnosis should be entertained in all patients with chronic constipation presenting to gastroenterologists, and a good rectal examination can help guide you as to whether anorectal manometry testing is warranted.

10. *Finishing up:* Remove the finger and inspect for obvious blood, mucus or pus, and note the feces color. I do not perform guaiac testing; it is often misleading (6). If there is persistent gaping of the anal canal after withdrawal, this suggests there may be an external anal sphincter or neurological defect.

Perhaps the issues surrounding rectal examinations and physician reluctance really have not changed. In the last century William Mayo said, “The examining physician often hesitates to make the necessary examination because it involves soiling the finger.” The only valid reasons why a gastroenterologist should fail to perform a proper rectal examination as part of the clinical evaluation in 2008 are (a) the gastroenterologist has lost all of his or her fingers or (b) the patient is acutely ill and therefore there is a clear cut temporary contraindication. Your physical examination is usually incomplete without performing the rectal!

Reprint requests and correspondence: Nicholas J. Talley, M.D., Ph.D., Mayo Clinic College of Medicine, Jacksonville, Florida, 4500 San Pablo Rd, Jacksonville, FL 32224.

REFERENCES

1. Talley NJ, O’Connor S. Clinical examination: A systematic guide to physical diagnosis, 5th edition. Sydney: Churchill Livingstone: Elsevier, 2006 160–1.
2. Dobben AC, Terra MP, Deutekom M, et al. Anal inspection and digital rectal examination compared to anorectal physiology tests and endoanal ultrasonography in evaluating fecal incontinence. *Int J Colorectal Dis* 2007;22: 783–90.

3. Bharucha AE, Fletcher JG, Seide B, et al. Phenotypic variation in functional disorders of defecation. *Gastroenterology* 2005;128:1199–210.
4. Rao P, Tantiphlachiva K, Attaluri A, et al. How useful is the rectal examination in the diagnosis of dyssynergia? *Am J Gastroenterol* 2007;102:S268.
5. Rao SS, Seaton K, Miller M, et al. Randomized controlled trial of biofeedback, sham feedback, and standard therapy for dyssynergic defecation. *Clin Gastroenterol Hepatol* 2007;5:331–8.
6. Longstreth GF. Checking for “the occult” with a finger. A procedure of little value. *J Clin Gastroenterol* 1988;10:133–4.

CONFLICT OF INTEREST

Guarantor of the article: Nicholas J. Talley, M.D., Ph.D.

Specific author contributions: N/A.

Financial support: None.

Potential competing interests: None.
