

The Tanner Stages

Because the onset and progression of puberty are so variable, Tanner has proposed a scale, now uniformly accepted, to describe the onset and progression of pubertal changes (Fig. 9-24). Boys and girls are rated on a 5 point scale. Boys are rated for genital development and pubic hair growth, and girls are rated for breast development and pubic hair growth.

Pubic hair growth in females is staged as follows (Fig 9-24, B):

- **Stage I (Preadolescent)** - Vellos hair develops over the pubes in a manner not greater than that over the anterior wall. There is no sexual hair.
- **Stage II** - Sparse, long, pigmented, downy hair, which is straight or only slightly curled, appears. These hairs are seen mainly along the labia. This stage is difficult to quantitate on black and white photographs, particularly when pictures are of fair-haired subjects.
- **Stage III** - Considerably darker, coarser, and curlier sexual hair appears. The hair has now spread sparsely over the junction of the pubes.
- **Stage IV** - The hair distribution is adult in type but decreased in total quantity. There is no spread to the medial surface of the thighs.
- **Stage V** - Hair is adult in quantity and type and appears to have an inverse triangle of the classically feminine type. There is spread to the medial surface of the thighs but not above the base of the inverse triangle.

The stages in male pubic hair development are as follows (Fig. 9-24, B):

- **Stage I (Preadolescent)** - Vellos hair appears over the pubes with a degree of development similar to that over the abdominal wall. There is no androgen-sensitive pubic hair.
- **Stage II** - There is sparse development of long pigmented downy hair, which is only slightly curled or straight. The hair is seen chiefly at the base of penis. This stage may be difficult to evaluate on a photograph, especially if the subject has fair hair.
- **Stage III** - The pubic hair is considerably darker, coarser, and curlier. The distribution is now spread over the junction of the pubes, and at this point that hair may be recognized easily on black and white photographs.
- **Stage IV** - The hair distribution is now adult in type but still is considerably less that seen in adults. There is no spread to the medial surface of the thighs.
- **Stage V** - Hair distribution is adult in quantity and type and is described in the inverse triangle. There can be spread to the medial surface of the thighs.

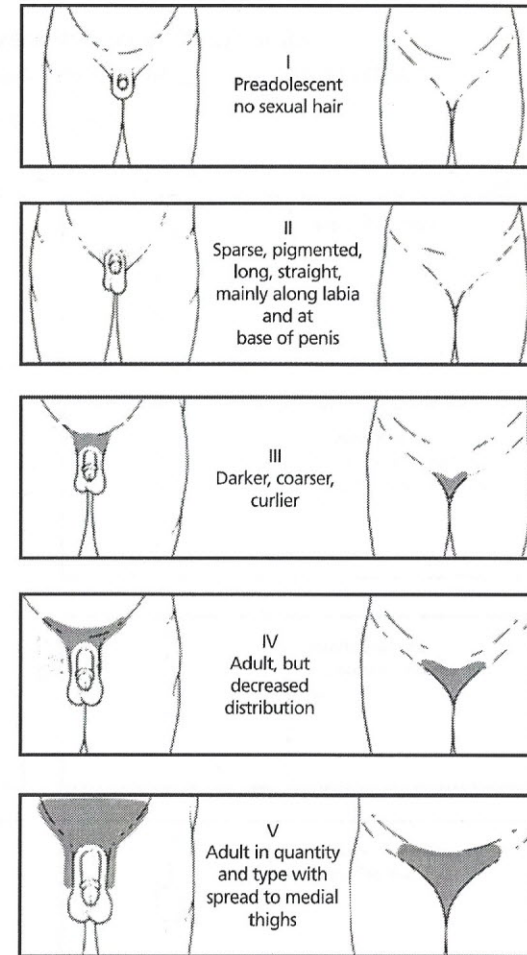


Fig. 9-24, B

In young women, the Tanner stages for breast development are as follows (Fig. 9-24, C):

- **Stage I (Preadolescent)** - Only the papilla is elevated above the level of the chest wall.
- **Stage II - (Breast Budding)** - Elevation of the breasts and papillae may occur as small mounds along with some increased diameter of the areolae.
- **Stage III** - The breasts and areolae continue to enlarge, although they show no separation of contour.
- **Stage IV** - The areolae and papillae elevate above the level of the breasts and form secondary mounds with further development of the overall breast tissue.
- **Stage V** - Mature female breasts have developed. The papillae may extend slightly above the contour of the breasts as the result of the recession of the areolae.

The stages for male genitalia development are as follows: (Fig. 9-24, A):

- **Stage I (Preadolescent)**- The testes, scrotal sac, and penis have a size and proportion similar to those seen in early childhood.
- **Stage II** - There is enlargement of the scrotum and testes and a change in the texture of the scrotal skin. The scrotal skin may also be reddened, a finding not obvious when viewed on a black and white photograph.
- **Stage III** - Further growth of the penis has occurred, initially in length, although with some increase in circumference. There also is increased growth of the testes and scrotum.
- **Stage IV** - The penis is significantly enlarged in length and circumference, with further development of the glans penis. The testes and scrotum continue to enlarge, and there is distinct darkening of the scrotal skin. This is difficult to evaluate on a black-and-white photograph.
- **Stage V** - The genitalia are adult with regard to size and shape.

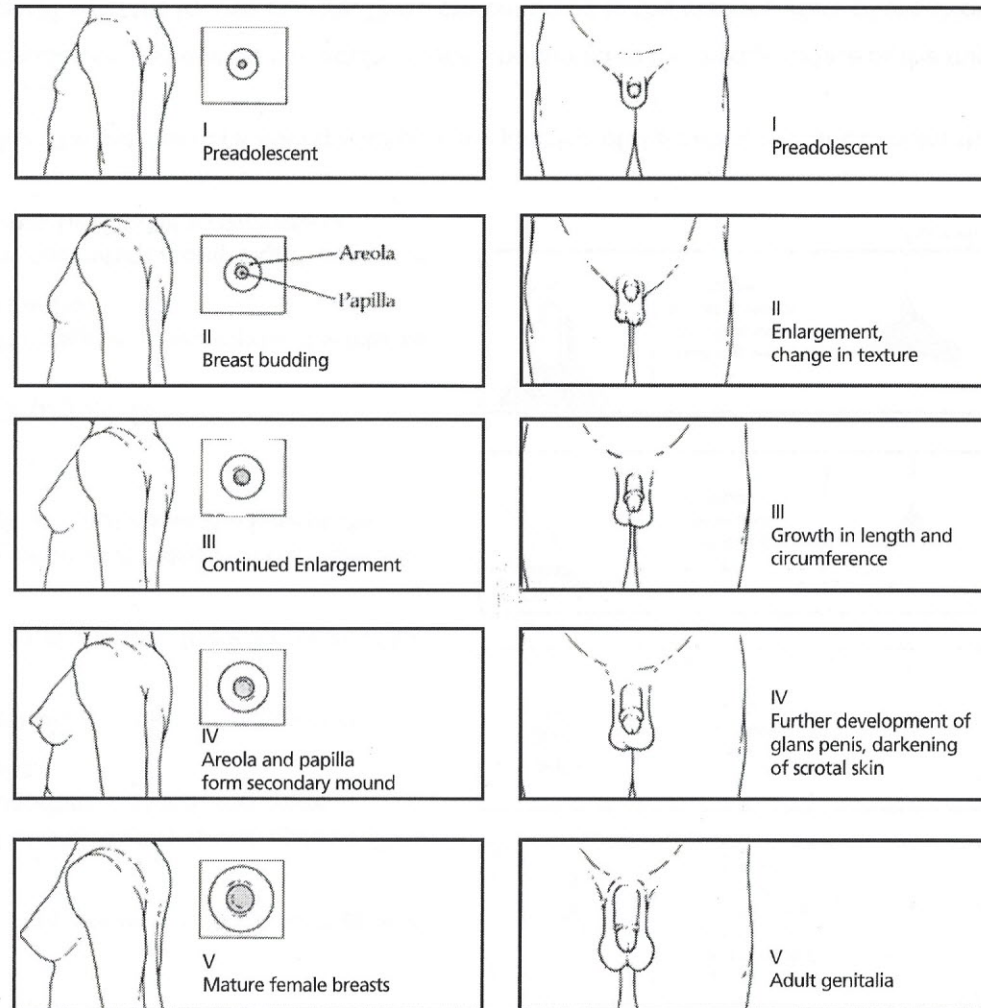


Fig. 9-24, C

Fig. 9-24, A

Source:

Reprinted with permission from Feingold, David. "Pediatric Endocrinology" In *Atlas of Pediatric Physical Diagnosis, Second Edition*, Philadelphia. W.B. Saunders, 1992, 9.16-19