

## Glossary of terms in child sexual abuse.

\*Modified from APSAC Descriptive Terminology in Child Sexual Abuse


- Abrasion** An area of body surface denuded of skin or mucous membrane by some unusual or abnormal mechanical process. An injury.
- Elasticity** The state or quality of being distensible. Flexibility; adaptability. Example: A hymen that changes its configuration with the different examination methods and/or positions.
- Estrogenized** Effect of the female sex hormone, estrogen, on the genitalia. The hymen takes on a thickened, redundant and pale pink appearance as the result of estrogenization. *These changes are observed in infants, with the onset of puberty, and as the result of exogenous estrogen.*
- Friability** A term used to describe tissues that bleed (abnormally) easily. Example: The friability of labial adhesions, that when gently separated may bleed. Friability of the posterior fourchette – A superficial breakdown of the skin in the posterior fourchette (commissure) when gentle traction is applied causing slight bleeding. *A non-specific finding due to many different underlying causes.*
- Hyperemia** An excess of blood in a part; engorgement of the blood vessels. *(A non-specific finding.)*
- Intracural Intercourse** The act of rubbing the penis between the labia of the female without entering the vagina. *(Also termed intralabial, dry or vulvar intercourse)*
- Labia Majora** Rounded folds of skin forming the lateral boundaries of the vulva. *Commonly injured in accidental straddle injuries.*
- Labia Minora** Longitudinal, thin folds of tissue within the labia majora. In the prepubertal child, these folds extend from the clitoral hood to approximately the midpoint on the lateral wall of the vestibule. In the adult, they enclose the vestibule and contain the opening to the vagina. *Commonly injured in accidental straddle injuries.*
- Labial Adhesion** The result of adherence (fusion) of the adjacent, outer-most, mucosal surfaces of the posterior portion vestibular walls. This may occur at any point along the length of the vestibule although it most commonly occurs posteriorly (inferiorly). *A common finding in infants and young children. Unusual to appear for the first time after 6 to 7 years of age. May be related to chronic irritation. (Also called labial agglutination.)*
- Linea Vestibularis** A vertical, pale/avascular line across the posterior fourchette and/or fossa navicularis, which may be accentuated by putting lateral traction on the labia majora. *A common finding that is found in girls of all ages including newborns and adolescents.*

|                                            |                                                                                                                                                                                                                                                                                                         |
|--------------------------------------------|---------------------------------------------------------------------------------------------------------------------------------------------------------------------------------------------------------------------------------------------------------------------------------------------------------|
| <b>Laceration</b>                          | A transaction (cut) through the skin, mucous membranes or deeper structures of the body. A tear through the full thickness of the skin or other tissue.                                                                                                                                                 |
| <b>Leukorrhoea</b>                         | A whitish, viscid (glutinous) discharge from the vagina and uterine cavity through the cervical os. <i>A normal finding in adolescent and adult females. (The term physiologic discharge is sometimes used.)</i>                                                                                        |
| <b>Petechiae</b>                           | Small, pinhead sized hemorrhages caused by leaking capillaries. May be singular or multiple. <i>Frequently caused by increased pressure within the blood vessel, as with straining during vomiting or with strangulation. May also be caused by a bleeding disorder, infection or localized trauma.</i> |
| <b>Scar</b>                                | Fibrous tissue which replaces normal tissue after the healing of a wound. <i>May be difficult to prove on clinical grounds alone, such as during visual inspection or palpation.</i>                                                                                                                    |
| <b>Transection</b>                         | A cutting across. Division by cutting or tearing transversely.                                                                                                                                                                                                                                          |
| <b>Complete</b>                            | A tear or laceration through the entire width of the hymenal membrane extending from its edge to the vaginal wall attachment.                                                                                                                                                                           |
| <b>Partial</b>                             | A tear or laceration through a portion of the hymenal membrane not extending to the attachment to the vaginal wall.<br><i>The strict definition of the term "transaction" implies a complete tear through the entire width of a membrane. Therefore, the use of the term partial tear is suggested.</i> |
| <b>Vascularity, increased or prominent</b> | Dilation of existing superficial blood vessels.                                                                                                                                                                                                                                                         |
| <b>Vulvar Coitus</b>                       | Rubbing of the penis between the labia of the female without entering the vagina. <i>(Also called intralabial, dry or intracruel intercourse.)</i>                                                                                                                                                      |

### **Terminology involving the hymenal anatomy**

|              |                                                                                                                                                                                                                                                                                                                                                                                                                                                                                                                                                                                                                    |
|--------------|--------------------------------------------------------------------------------------------------------------------------------------------------------------------------------------------------------------------------------------------------------------------------------------------------------------------------------------------------------------------------------------------------------------------------------------------------------------------------------------------------------------------------------------------------------------------------------------------------------------------|
| <b>Hymen</b> | A membrane which partially or rarely, completely covers the external vaginal orifice. Located at the junction of the vestibular floor and the vaginal canal. The external surface is lined with highly differentiated squamous epithelium with loose cornification. The internal surface is lined with vaginal epithelium. Origin is the external vaginal plate of the urogenital sinus.<br>Wide anatomic variation in types: annular, crescentic, fimbriated (denticular), septate, cribriform, imperforate. <i>All females with a normal Mullerian system and normal external genitalia have this structure.</i> |
|--------------|--------------------------------------------------------------------------------------------------------------------------------------------------------------------------------------------------------------------------------------------------------------------------------------------------------------------------------------------------------------------------------------------------------------------------------------------------------------------------------------------------------------------------------------------------------------------------------------------------------------------|

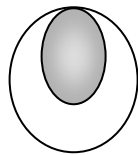
**Annular** The hymenal membrane extends completely around the circumference of the vaginal orifice.



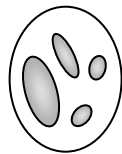**Caruncular Myrtiformis** Small elevations of rounded mounds of hymen encircling the vaginal orifice. *Found in sexually active and postpartum females. (Also called Caruncular hymenales)*

**Cleft/notch** An angular or "V"-shaped indentation on the edge of the hymenal membrane. May extend to the muscular attachment of the hymen.

**Crescentic** Hymen with anterior attachments at approximately the 11 o'clock and the 1 o'clock positions with no hymenal tissue visible between the two attachments. *The most common hymenal configuration in the school aged, prepubertal child.*



**Cribriform** A hymen with multiple openings. A congenital variant.

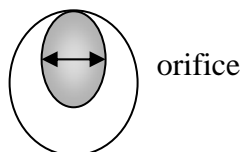


**Erythema of the Hymen** A redness of the hymenal membrane produced by congestion [engorgement] of the capillaries. *A non-specific finding. May result from a variety of irritants as well as direct trauma.*

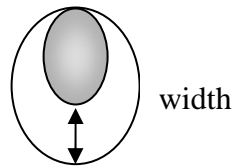
**Fimbriated** Hymen with multiple projections or indentations along the edge, creating ruffled appearance. *A congenital variant. (Also called denticular hymen.)*

**Hymenal Orifice** The opening in the hymenal membrane which constitutes the entrance or outlet of the vagina.

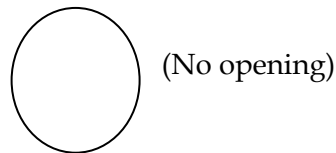
**Hymenal Orifice's Diameter** The distance from one edge of the hymen to the opposite edge of the hymenal orifice. The most common measurement used is the horizontal (lateral) diameter. *Hymenal orifice size varies with the age of the child, the examination technique and other factors such as the state of relaxation.*



**Hymenal Width** The distance between the opening of the hymen and its point of attachment.



**Imperforate** A hymenal membrane with no opening. *An uncommon congenital variant.*



**Inflammation (Hymenal)** A localized protective response elicited by injury or destruction of tissues. *A non-specific finding that can result from a variety of causes including trauma.*

**Intravaginal Columns** Raised (sagittally oriented) columns most prominent on the anterior wall with less prominence on the posterior wall.

**Laceration of the Hymen** An injury or tear of the hymenal membrane that is usually associated with a blunt force penetration.

**Median (Perineal) Raphe** A ridge or furrow that marks the line of union of the two halves of the perineum.

**Mound (Bump)** A solid, localized, rounded and thickened area of tissue on the edge of the hymen.

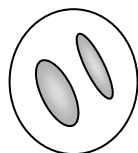
**Notch/cleft (Hymenal)** An angular or "V" shaped indentation on the edge of the hymenal membrane. May extend to the muscular attachment of the hymen. *A relatively sharp, "V"-shaped notch or cleft, that persists during multiple examination techniques may be evidence of hymenal trauma.*

**Perihymenal** Pertaining to tissues surrounding the hymen.

**Perihymenal Bands** Bands of tissue lateral to the hymen that form a connection between the perihymenal structures and the wall of the vestibule. *A less frequently observed finding than periurethral bands. Accentuated when the labial traction examination method is used. Usually a congenital variant. Rarely caused by trauma. (Also termed pubo-vaginal bands.)*

**Redundant Hymen** Abundant hymenal tissue which tends to fold back upon itself or protrude. *A common finding in females whose hymenal membranes are under the influence of estrogen (both infants and adolescents).*

- Rolled Edges** The edge (border) of the hymen which tends to roll inward or outward upon itself. May unfold through the use of the knee-chest position, application of water, through manipulation with a moistened Q-tip or other techniques. *A normal variant most commonly noted in prepubertal children.*
- Rounded Edges** Hymenal edges that appear thick and rounded and do not thin out with the different examination techniques, the application of water or other maneuvers used to unroll an elastic, redundant hymen. *May be the result of hormonal influence, poor relaxation, and inflammatory reaction, the attachment of an underlying intravaginal longitudinal ridge or past injury.*
- Scalloped Edges** A series of rounded projections along the edge of the hymen. *A common finding in early adolescence.*
- Septal Remnant** A small appendage (tag) attached to the edge of the hymen. Commonly located in the midline on the posterior rim. Frequently associated with a concomitant thickened ridge on the hymen which extends from the appendage (septal remnant) to the muscular attachment of the vaginal introitus. May be associated with similar appendage on opposite side of hymenal orifice. (Similar to hymenal tags.) *Considered to be a normal variant. A diagnosis by implication unless an intact septum was previously seen.*
- Septated Hymen** A hymen with band(s) of tissue, which bisects the orifice creating two or more openings. *A congenital variant.*



- Tag (Hymenal)** An elongated projection of tissue arising from any location on the hymenal rim. Commonly found in the midline and may be an extension of a posterior vaginal ridge. *Usually a congenital variant. Rarely caused by trauma.*
- Transection of hymen, complete** A tear or laceration through the entire width of the hymenal membrane, extending to (or through) its attachment to the vaginal wall.
- Transection of hymen, partial** A tear or laceration through a portion of the hymenal membrane, not extending to its attachment to the vaginal wall. *The strict definition of the term "transaction" implies a complete tear through the entire width of a membrane. Therefore, the use of the term "partial transaction" is less desirable. The term partial tear is suggested.*
- Vaginal Introitus** The pubovaginalis muscle which forms the entrance to the vagina. Frequently used synonymously with hymenal orifice.
- Vaginitis** Inflammation of the vagina; it may be marked by a purulent discharge and discomfort. *May be caused by a variety of conditions, including bacterial vaginosis, sexually transmitted diseases, foreign bodies, to name a few.*

## Terminology involving the anal anatomy

- Anal Fissure** A superficial break (split) in the perianal skin which radiates out from the anal orifice. *A variety of causes including the passage of hard stools (constipation), diseases such as Crohn's Disease and trauma. Can heal without leaving visible scars.*
- Anal Laxity** Decrease in muscle tone of the anal sphincters resulting in dilation of the anus. *May occur immediately following an acute/forced sodomy.*
- Anal Skin Tag** A protrusion of anal verge tissue which interrupts the symmetry of the perianal skin folds. A projection of tissue on the perianal skin. *When located outside the midline, causes, other than a congenital variation should be considered, including such things as Crohn's disease or trauma.*
- Anal Spasm** An involuntary contraction of the anal sphincter muscles. May be attended by pain and interference with function. *May be found immediately post assault.*
- "Anal Wink"** Reflex anal sphincter muscle contraction as a result of stroking the perianal skin. Used to determine sensory nerve function. *Relationship to sexual abuse is unknown.*
- Diastasis Ani (Smooth Area)** A smooth, often "V" or wedge shaped area at either the 6 or 12 o'clock positions in the perianal region. It is due to the absence of the underlying corrugator external anal sphincter muscle and results in a loss of the usual anal skin folds in the area. *A congenital variant.*
- Ecchymosis of the Perianal Tissues** A hemorrhagic area (bruise) on the skin or mucous membrane of the perianal tissues due to extravasation of blood most commonly caused by external trauma. *May be confused with venous congestion and postmortem lividity.*
- Edema** The presence of abnormal amounts of fluid in the intercellular space. *If secondary to trauma, it will usually be accompanied by erythema, pain and swelling of perianal skin folds. (Also called tissue swelling.)*
- Flattened Anal Skin Folds** A reduction or absence of the perianal folds or wrinkles, noted when the external anal sphincter is partially or completely relaxed. *The relationship to sexual abuse is unknown. A common finding in sedated, relaxed children and at autopsy.*
- Funnel Appearance** A decrease in the fatty (subcutaneous) tissue surrounding the anus, leading to a concave appearance.
- Hyperpigmentation** Increase in melanin pigment within the perianal tissues. *A common congenital finding in darker skinned children. May be associated with post-inflammatory changes.*
- Intermittent and Dilation** Anus dilates intermittently during examination, particularly in the prone knee-chest position. *A common finding in children of all ages.*

**Perianal Venous Congestion** The collection of venous blood in the venous plexus of the peri-anal tissues creating a flat, purple discoloration. May be localized or diffuse. *A common finding in children when the thighs are flexed upon the hips for an extended period of time. (Also termed perianal venous engorgement or perianal venous pooling.)*

**Reflex Anal Dilatation** Anal dilation which occurs upon stroking the buttocks. *Once considered to be evidence of prior sexual abuse. Relationship to sexual abuse is currently unclear.*